

PATIENTS AND METHODS

This retrospective study reviewed outcomes of the first 35 consecutive cases of DSEK performed by a single surgeon (K.C.) using donor graft tissue that had undergone prelamellar dissection, trephination, and loading into EndoGlide Ultrathin inserters at the Lions Eye Institute for Transplant and Research (Tampa, FL) and shipped overnight in Optisol GS (Bausch & Lomb, Rochester, NY) to the surgeon. The Institutional Review Board at Massachusetts Eye and Ear Infirmary approved this study, which was conducted in accord with the Declaration of Helsinki and the Health Insurance Portability and Accountability Act.

The series consists of 35 eyes of 34 consecutive patients who underwent DSEK from March 2013 to March 2014 at the Massachusetts Eye and Ear Infirmary either for Fuchs endothelial dystrophy ($n = 29$) or for previously failed full-thickness grafts ($n = 6$). ECD was measured by specular microscopy at 3, 6, and 12 months and was compared with the preoperative eye bank measurements. The size of the recipient bed and the donor disc was 8.0 mm in 32 cases and 7.5 mm in 3 cases. All 3 cases in which a 7.5-mm donor disc was used had previously failed penetrating keratoplasties. Combined cataract surgery and endothelial replacement surgery was not performed in any of the reported cases.

Preoperative specular microscopy of the donor tissue was performed by the same experienced technician at the Lions Eye Institute for Transplant and Research using a Konan Cell Check EB-10 specular microscope (Konan Medical USA, Irvine, CA) after donor tissue trephination and before loading it into the EndoGlide Ultrathin inserter. An apices digitized method and the manufacturer's calibrations for magnification were used to obtain these preoperative cell counts. At least 100 cells from each cornea were counted. Postoperative ECD measurements were done with a Heidelberg Retina Tomograph 3 (Heidelberg Engineering, Heidelberg, Germany) by the same technician who was masked as to whether the patients were part of this study. Postoperative pachymetry was performed by an experienced ophthalmic technician using an RK 500 ultrasonic pachymeter (KMI Surgical Products, Westchester, PA). Measurements were taken in triplicate and the average of the 3 measurements was used.

The main outcome measures included intraoperative and postoperative complications and ECD loss at 3, 6, and 12 months. Secondary outcome measures were mean best-corrected vision and mean CCT at the last follow-up visit.

Surgical Technique

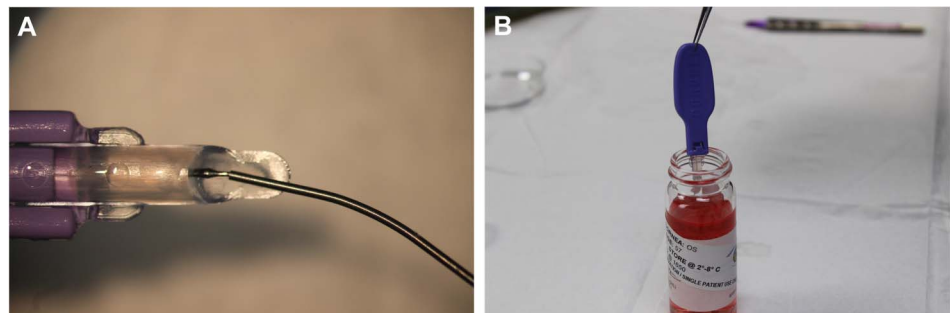
The donor tissue was prepared at the Lions Eye Institute for Transplant and Research with a Moria microkeratome, trephined with corneal punch, and then loaded into the EndoGlide Ultrathin inserter (Fig. 1A). This inserter can be used for tissue as thin as 50 μm and as thick as 200 μm . The tissue within the EndoGlide was then placed inside a vial with 20 mL of Optisol GS and was stored at a temperature of 2 to 8°C (Fig. 1B). It was then shipped overnight to the surgeon (K.C.) and surgery was performed within 24 hours from graft preparation and loading into the EndoGlide by the Eye Bank. One to 2 hours before surgery, the sealed vial containing the preloaded tissue was removed from the shipping container and was allowed to reach ambient temperature. About 10 minutes before transplantation of the donor tissue, the preloaded EndoGlide Ultrathin inserter was removed from the storage vial in a sterile fashion and immersed in balanced salt solution Plus irrigating solution to dilute the hypertonic Optisol GS.

Surgery was performed using a retrobulbar or peribulbar block with monitored intravenous sedation. A temporal scleral tunnel 5-mm wide and 1.5-mm deep was first constructed. A 1.5-mm opening into the anterior chamber (AC) was made with a supersharp blade. An AC maintainer was placed through an inferior paracentesis incision. A nasal paracentesis incision was also made opposite to the temporal main incision. The circumference of the planned area of Descemet membrane removal was marked on the anterior surface of the cornea. The Descemet membrane was scored in a circular pattern with a reverse Sinsky hook and removed from the eye. This was done entirely under balanced saline solution and no viscoelastic was used at any time during this procedure.

The scleral tunnel was opened completely using a 4.9-mm Sharp point disposable knife. With the AC maintainer on moderate flow (about 40–50 mm Hg), the preloaded EndoGlide was inserted through the temporal wound and advanced into the AC. Curved EndoGlide insertion forceps (Coronet, Model 53-951, Reading, PA) were inserted through the nasal paracentesis and used to engage the stromal side of the donor tissue that was removed from the EndoGlide cartridge into the AC. Once in the AC, the tissue usually unfolded into position spontaneously. If one wing remained slightly curled, gently shaking the donor tissue with the forceps assisted in unfolding it.

As the donor tissue was stabilized with the forceps, the EndoGlide cartridge was removed from the eye. A small

FIGURE 1. A, The DSEK donor tissue is seen within the EndoGlide Ultrathin inserter after preparation and preloading at the Lions Eye Institute for Transplant and Research (Tampa, FL). B, Photograph of the preloaded EndoGlide Ultrathin inserter being placed in the vial of Optisol GS.



amount of air was injected beneath the donor tissue with a cannula to ensure that the donor continued to float up against the recipient stromal surface. The forceps were removed from the nasal paracentesis and the main wound was sutured closed. A complete air fill was maintained for 12 minutes. Some of the air was then released, and the patient remained supine for 1 hour in the postoperative care unit before being discharged home. Surgical iridectomy was not performed. The postoperative regimen included prednisolone acetate 1% 4 times a day for 2 weeks, with gradual taper to once daily, moxifloxacin 0.5% 4 times a day for 1 week, and sodium chloride 5% 4 times daily for 2 to 4 weeks.

Statistical Analysis

Statistical analysis was performed using GraphPad Prism software (La Jolla, CA). Basic descriptive statistics were calculated on all data and are reported as mean \pm SD.

RESULTS

Patient and Donor Characteristics

The 35 eyes in this retrospective noncomparative series were from 34 consecutive patients with a mean age at the time of surgery of 70.5 years (range, 49–91). The baseline characteristics of the study eyes are summarized in Table 1. Mean preoperative vision was 20/100, with a range of 20/25 to hand motions, and mean preoperative CCT was 711 μ m (range, 514 to >1000).

Donor tissue characteristics and operative details are provided in Table 2. The mean preoperative ECD was 2821 cells/mm² (range, 2433–3185), and the mean DSEK graft thickness was 120 μ m (range, 91–149). All grafts were 8.0 mm in diameter except 3 grafts that were used in cases of DSEK placed into failed penetrating keratoplasty.

Intraoperative and Postoperative Complications

One preloaded graft was folded incorrectly within the EndoGlide Ultrathin inserter. Yet, it was placed successfully and no postoperative detachment or dislocation was noted; the graft cleared within 6 weeks. The second intraoperative

TABLE 1. Baseline Characteristics of 35 Eyes That Underwent DSEK With Eye Bank-Prepared Preloaded Grafts

	35 Eyes
No. patients	34
Female, n (%)	13 (27)
Age, mean \pm SD, yr	70.5 \pm 10
Preoperative vision, mean (range)	20/100 (20/25–HM)
Preoperative CCT, mean \pm SD, μ m	711 \pm 109
Indication for surgery, n (%)	
Fuchs endothelial dystrophy	29 (83)
Failed full-thickness grafts	6 (17)

HM, hand motions.

TABLE 2. Donor Tissue Characteristics of 35 Eye Bank-Prepared and Preloaded DSEK Grafts

	35 Grafts
Donor age, mean \pm SD, yr	59 \pm 13
Death-to-preservation time, mean \pm SD, h	11 \pm 4.5
Donor lens status, n (%)	
Phakic	1 (3)
Pseudophakic	34 (97)
Graft thickness, mean \pm SD, μ m	120 \pm 16
Donor graft diameter, n (%)	
8.0 mm	32 (91)
7.5 mm	3 (9)
Preoperative ECD, mean \pm SD, cells/mm ²	2821 \pm 199

complication involved a graft that was found to be wrinkled within the EndoGlide Ultrathin inserter. Although the graft was attached at the first postoperative day, it was found detached 5 days later. Because the graft was not loaded properly in the inserter and the endothelium may have been irreversibly damaged, decision was made to replace the graft, which was done without incident. Both intraoperative issues were noted within the first 10 surgeries performed using this method. The Lions Eye Institute for Transplant and Research (Tampa, FL) was notified of both instances and appropriate measures were taken.

Postoperative complications included 2 cases of partial graft detachment in the group for an incidence of 5.7%. Both grafts were reattached successfully with air bubble replacement and repositioning. There was one episode of graft rejection at 6 months, representing an incidence of 2.8%. No other significant postoperative complications were noted.

Endothelial Cell Counts, Vision, and Pachymetry

Baseline and postoperative mean ECD and percent endothelial cell loss at 3, 6, and 12 months are presented in Table 3. For all 35 eyes that completed 3 months of follow-up, mean ECD was 2112 \pm 453 cells/mm² for a mean ECD loss of 25.8% \pm 14.2%, and it remained overall stable at

TABLE 3. ECD Loss With Eye Bank Preloaded DSEK Grafts

	Mean (SD)	N
ECD, cells/mm ²		
Preoperative	2821 (199)	35
1.5–3 mo	2112 (453)	35
4.5–6 mo	2096 (494)	32
1 yr	1953 (541)	32
At the last follow-up visit	1954 (513)	35
Endothelial cell loss, %		
1.5–3 mo	25.8 (14.2)	35
4.5–6 mo	25.3 (17.2)	32
1 yr	31.5 (17.9)	32
At the last follow-up visit	31.1 (17.9)	35

1954 ± 513 cells/mm² until the last follow-up visit at 11.7 ± 2.7 months.

Mean best-corrected visual acuity of all patients improved from 20/100 (range, 20/25 to hand motions) preoperatively to 20/25 (range, 20/20–20/50) postoperatively at a mean follow-up of 11.7 ± 2.7 months. Similarly, mean CCT of all patients improved from 711 μm (range, 514 to >1000) preoperatively to 638 μm (range, 522–860) at 11.7 ± 2.7 months postoperatively.

DISCUSSION

Our results suggest that eye bank-prepared preloaded corneal grafts can be successfully used for DSEK with minimal complications. Both cases of incorrectly folded donor tissues occurred early in this series and can be attributed to the learning curve of the eye bank technicians preparing these grafts. At a mean follow-up of 11.7 ± 2.7 months, there was one episode of graft rejection in this group of 35 eyes representing an incidence of 2.8%. This falls well within the expected 1-year rejection rate after DSEK, which is estimated to be 7.6% by 1 year and 12% by 2 years as per Kaplan–Meier survival analysis of the largest series to date (n = 598).⁹ There were 2 cases of graft detachment for a rate

of 5.7%, and both were treated successfully with replacement of air in the AC. Reported graft dislocation rates in the literature range from as low as 0% to as high as 82%.^{6,10–18}

ECD loss using preloaded tissue is comparable to a wide variety of previously reported techniques and methods (Table 4).^{5–8,10,13,18–33} Mean ECD loss was 25.8% at 3 months, 25.3% at 6 months, and 31.5% by 1 year. This study was not designed to directly compare the endothelial cell loss using preloaded tissue with endothelial cell loss following other insertion techniques, including day-of-surgery loading into the EndoGlide Ultrathin inserter.

Using eye bank-prepared preloaded grafts reduces surgical time and intraoperative tissue manipulation by the surgeon. Moreover, donor tissue preparation and preloading by trained eye bank technicians would result in better standardization, more experienced donor manipulation, and less variation in the surgical technique and expertise at this crucial stage of donor manipulation, when endothelial cell loss may occur. Reducing the surgical variability at the eye bank stage by relegating this surgical step to trained eye bank technicians who will develop high skill levels and consistency by virtue of repeatability and experience, compared with the variability of donor preparation by individual surgeons with variable experience, should result in reduced endothelial

TABLE 4. Mean ECD Loss for DSEK With Various Graft Insertion Techniques

Author (yr)	Graft Insertion Technique	Mean % ECD Loss at 6 mo (No. Eyes)	Mean % ECD Loss at 12 mo (No. Eyes)
Palioura and Colby (2016)	Preloaded Ultrathin EndoGlide	25.3 (32)	31.5 (32)
Elbaz et al ⁷	EndoGlide	38.6 (10)	41.2 (10)
	EndoSerter	30.1 (10)	31.4 (10)
	Sheets glide	—	29.5 (119)
Ang et al ¹⁹	EndoGlide	—	16.3 (100)
	Forceps (40/60 taco fold)	25.0 (50)	—
Terry et al ²⁰	Neusidl inserter	33.0 (50)	—
	EndoGlide	13.5 (61)	14.9 (12)
Khor et al ⁸	Multiple techniques	36.4 (45)	—
Tourtas et al ²¹	EndoGlide	25.7 (22)	—
Gangwani et al ²²	Busin glide	47.5 (30)	—
	Sheets glide	—	29.5 (113)
Ang et al ²³	Forceps (trifold)	44.1 (52)	—
Foster et al ²⁴	EndoGlide	13.1 (20)	15.6 (10)
Khor et al ¹⁶	Forceps (40/60 taco fold)	26.0 (305)	27.0 (205)
Chen et al ²⁵	Forceps (taco fold)	34 (131)	38 (111)
Price et al ²⁶	Modified Busin glide	25.0 (16)	—
Bahar et al ¹⁰	Forceps (60/40 taco fold)	34.3 (25)	—
Terry et al ¹⁸	Forceps (60/40 taco fold)	31.0 (65)	29 (61)
Price and Price ²⁷	Forceps (taco fold)	34.0 (263)	36.0 (34)
Kobayashi et al ²⁸	Multiple techniques	54.0 (14)	—
Terry et al ²⁹	Forceps (60/40 taco fold)	—	36.0 (319)
Bahar et al ³⁰	Suture pull-through	—	36.4 (45)
Busin et al ⁵	Busin glide	20.0 (10)	23.5 (10)
Mehta et al ³¹	Sheets glide	25.3 (10)	—
Sarnicola and Toro ³²	Suture pull-through	—	30.0 (16)
Kaiserman et al ³³	Suture pull-through	39.4 (8)	—
Koenig et al ¹³	Forceps (60/40 taco fold)	37.8 (20)	—
	Forceps (taco fold)	50 (30)	—

damage, analogous to better consistency and outcomes achieved by eye banks performing pre-lamellar dissection of donor tissue with microkeratomes.

One disadvantage of using preloaded grafts is that the diameter of the desired graft has to be decided preoperatively. This can be done by measuring the patient's corneal diameter at the slit lamp during one of the preoperative clinic visits. Overall, we have found that 8.0-mm donor grafts are suitable for the majority of our patients. For failed penetrating keratoplasty patients, a smaller graft of 7.5 mm is advised to avoid overlap of the graft–host junction by the DSEK graft.

Limitations of this study are its retrospective nature and a lack of side-by-side comparison with DSEK using a different insertion method. However, our complication rate and ECD loss rate compare favorably with previously published series. This study was not designed to directly compare the endothelial cell loss using preloaded tissue with endothelial cell loss following other insertion techniques, including day-of-surgery loading into the EndoGlide Ultrathin inserter.

Finally, this study underscores the importance of fruitful collaboration between corneal surgeons and eye banks for better patient care. Developing eye bank-prepared preloaded tissue grafts for DMEK is the logical next step, and this can potentially make DMEK easier to perform and more widely accepted within the cornea community.

ACKNOWLEDGMENTS

The authors thank Patrick Gore, Lynn Forest-Smith, Nicholas Sprehe, Dan Schallenkamp, and David Morton from the Lions Eye Institute for Transplant and Research (Tampa, FL) for a productive collaboration and helpful discussions. The authors also thank Stephanos Camarinopoulos for his kind assistance with the statistical analysis.

REFERENCES

- Price FW Jr, Whitson WE, Marks RG. Progression of visual acuity after penetrating keratoplasty. *Ophthalmology*. 1991;98:1177–1185.
- Elder MJ, Stack RR. Globe rupture following penetrating keratoplasty: how often, why, and what can we do to prevent it? *Cornea*. 2004;23:776–780.
- Lee WB, Jacobs DS, Musch DC, et al. Descemet's stripping endothelial keratoplasty: safety and outcomes: a report by the American Academy of Ophthalmology. *Ophthalmology*. 2009;116:1818–1830.
- Melles GR, Ong TS, Ververs B, et al. Descemet membrane endothelial keratoplasty (DMEK). *Cornea*. 2006;25:987–990.
- Busin M, Bhatt PR, Scorcia V. A modified technique for descemet membrane stripping automated endothelial keratoplasty to minimize endothelial cell loss. *Arch Ophthalmol*. 2008;126:1133–1137.
- Khor WB, Mehta JS, Tan DT. Descemet stripping automated endothelial keratoplasty with a graft insertion device: surgical technique and early clinical results. *Am J Ophthalmol*. 2011;151:223–232.
- Elbaz U, Yeung SN, Lichtinger A, et al. EndoGlide versus EndoSert for the insertion of donor graft in descemet stripping automated endothelial keratoplasty. *Am J Ophthalmol*. 2014;158:257–262.
- Khor WB, Han SB, Mehta JS, et al. Descemet stripping automated endothelial keratoplasty with a donor insertion device: clinical results and complications in 100 eyes. *Am J Ophthalmol*. 2013;156:773–779.
- Price MO, Jordan CS, Moore G, et al. Graft rejection episodes after Descemet stripping with endothelial keratoplasty: part two: the statistical analysis of probability and risk factors. *Br J Ophthalmol*. 2009;93:391–395.
- Bahar I, Kaiserman I, Sansanayudh W, et al. Busin Guide vs forceps for the insertion of the donor lenticule in descemet stripping automated endothelial keratoplasty. *Am J Ophthalmol*. 2009;147:220–226.
- Clements JL, Bouchard CS, Lee WB, et al. Retrospective review of graft dislocation rate associated with descemet stripping automated endothelial keratoplasty after primary failed penetrating keratoplasty. *Cornea*. 2011;30:414–418.
- Gorovoy MS. Descemet-stripping automated endothelial keratoplasty. *Cornea*. 2006;25:886–889.
- Koenig SB, Covert DJ, Dupps WJ Jr, et al. Visual acuity, refractive error, and endothelial cell density six months after Descemet stripping and automated endothelial keratoplasty (DSEK). *Cornea*. 2007;26:670–674.
- Mearza AA, Qureshi MA, Rostron CK. Experience and 12-month results of descemet-stripping endothelial keratoplasty (DSEK) with a small-incision technique. *Cornea*. 2007;26:279–283.
- Melles GR, Eggink FA, Lander F, et al. A surgical technique for posterior lamellar keratoplasty. *Cornea*. 1998;17:618–626.
- Price MO, Baig KM, Brubaker JW, et al. Randomized, prospective comparison of precut vs surgeon-dissected grafts for descemet stripping automated endothelial keratoplasty. *Am J Ophthalmol*. 2008;146:36–41.
- Suh LH, Yoo SH, Deobhakta A, et al. Complications of Descemet's stripping with automated endothelial keratoplasty: survey of 118 eyes at One Institute. *Ophthalmology*. 2008;115:1517–1524.
- Terry MA, Shamie N, Chen ES, et al. Precut tissue for Descemet's stripping automated endothelial keratoplasty: vision, astigmatism, and endothelial survival. *Ophthalmology*. 2009;116:248–256.
- Ang M, Saroj L, Htoon HM, et al. Comparison of a donor insertion device to sheets glide in Descemet stripping endothelial keratoplasty: 3-year outcomes. *Am J Ophthalmol*. 2014;157:1163–1169.
- Terry MA, Straiko MD, Goshe JM, et al. Endothelial keratoplasty: prospective, randomized, masked clinical trial comparing an injector with forceps for tissue insertion. *Am J Ophthalmol*. 2013;156:61–68.
- Tourtas T, Laaser K, Bachmann BO, et al. Descemet membrane endothelial keratoplasty versus descemet stripping automated endothelial keratoplasty. *Am J Ophthalmol*. 2012;153:1082–1090.
- Gangwani V, Obi A, Hollick EJ. A prospective study comparing EndoGlide and Busin glide insertion techniques in descemet stripping automated endothelial keratoplasty. *Am J Ophthalmol*. 2012;153:38–43.
- Ang M, Mehta JS, Lim F, et al. Endothelial cell loss and graft survival after Descemet's stripping automated endothelial keratoplasty and penetrating keratoplasty. *Ophthalmology*. 2012;119:2239–2244.
- Foster JB, Vasari R, Walter KA. Three-millimeter incision descemet stripping endothelial keratoplasty using sodium hyaluronate (healon): a survey of 105 eyes. *Cornea*. 2011;30:150–153.
- Chen ES, Phillips PM, Terry MA, et al. Endothelial cell damage in descemet stripping automated endothelial keratoplasty with the underfold technique: 6- and 12-month results. *Cornea*. 2010;29:1022–1024.
- Price MO, Gorovoy M, Benetz BA, et al. Descemet's stripping automated endothelial keratoplasty outcomes compared with penetrating keratoplasty from the Cornea Donor Study. *Ophthalmology*. 2010;117:438–444.
- Price MO, Price FW Jr. Endothelial cell loss after descemet stripping with endothelial keratoplasty influencing factors and 2-year trend. *Ophthalmology*. 2008;115:857–865.
- Kobayashi A, Yokogawa H, Sugiyama K. Descemet stripping with automated endothelial keratoplasty for bullous keratopathies secondary to argon laser iridotomy—preliminary results and usefulness of double-glide donor insertion technique. *Cornea*. 2008;27(suppl 1):S62–S69.
- Terry MA, Shamie N, Chen ES, et al. Endothelial keratoplasty: the influence of preoperative donor endothelial cell densities on dislocation, primary graft failure, and 1-year cell counts. *Cornea*. 2008;27:1131–1137.
- Bahar I, Kaiserman I, McAllum P, et al. Comparison of posterior lamellar keratoplasty techniques to penetrating keratoplasty. *Ophthalmology*. 2008;115:1525–1533.
- Mehta JS, Por YM, Poh R, et al. Comparison of donor insertion techniques for descemet stripping automated endothelial keratoplasty. *Arch Ophthalmol*. 2008;126:1383–1388.
- Sarnicola V, Toro P. Descemet-stripping automated endothelial keratoplasty by using suture for donor insertion. *Cornea*. 2008;27:825–829.
- Kaiserman I, Bahar I, McAllum P, et al. Suture-assisted vs forceps-assisted insertion of the donor lenticule during Descemet stripping automated endothelial keratoplasty. *Am J Ophthalmol*. 2008;145:986–990.